Acta Neuropathol (1990) 80:666–670

Acta Neuropathologica

Evolution of post-natal Herpes simplex virus encephalitis to multicystic encephalopathy

Y. Chang, D. Soffer, D. S. Horoupian, and L. M. Weiss

Department of Pathology, Stanford University School of Medicine, Stanford, CA 94305-5324, USA

Received January 9, 1990/Revised, accepted May 22, 1990

Summary. A 3-week-old, previously healthy infant developed biopsy-proven Herpes virus type 2 (HSV-2) encephalitis. The encephalitis was characterized by cells having intranuclear inclusions and was without evidence of inflammation or hemorrhage. Neuroimaging studies did not show any destructive lesions in the brain. In spite of antiviral therapy, the infant's neurological conditions deteriorated, and the patient died at the age of 18 weeks. Post-mortem examination showed that most of the cerebral hemispheres were replaced by multiloculated cystic cavities of various sizes, typical of multicystic encephalopathy (MCE). The cystic lesions were randomly distributed and were not confined to any vascular territory. By light microscopy, there were no features of viral infection in the brain. Although in situ hybridization of the biopsy specimen taken during the acute phase of the disease demonstrated abundant HSV genome, this same method failed to detect HSV on the post-mortem specimen. These findings suggest that HSV-2 can induce MCE. Furthermore, the absence of histological features of viral encephalitis and the failure to demonstrate viral genome in the brain at autopsy does not exclude an infectious etiology in certain cases of MCE.

Key words: Herpes simplex encephalitis – Multicystic encephalopathy – In situ hybridization

Multicystic encephalopathy (MCE), also known as multilocular cystic encephalopathy and neonatal polycystic encephalomalacia, is a rare condition characterized by multiple cavities of various sizes in the neonatal cerebral hemispheres [6]. MCE has been attributed to perinatal anoxia or ischemia [2], but some authors have challenged this assertion. Instead, they suggest that MCE is the final common result of a variety of insults to the immature central nervous system (CNS) including toxic as well as infectious agents, such as cytomegalovirus, *Proteus mirabils* and *Toxoplamsa gondii* [13]. In addition, cases have also been attributed to infection with Herpes simplex virus (HSV) [1, 5, 7, 9, 14, 16]. We present a case of neonatal HSV infection which documents the evolution of MCE and provides evidence for a viral etiology in certain cases.

Offprint requests to: D. S. Horoupian (address see above)

Case report

The patient was an 18-week-old full-term male infant who was delivered vaginally from a mother with no history of herpes infection. The infant was well until the age of 3 weeks when he became febrile, listless and irritable. Lumbar puncture revealed protein of 106 mg%, glucose 27 mg%, 358 erythrocytes and 93 leukocytes (93% mononuclear cells) per mm^2. Electroencephalogram (EEG) was consistent with severe encephalopathy, but magnetic resonance imaging (MRI) of the brain was unremarkable. At the age of 4 weeks the patient's neurological status worsened, accompanied by seizures. He became lethargic, hypotonic, and had weak suck and gag reflexes. Follow-up MRI showed loss of gray/white matter demarcation (Fig. 1A). A left temporal brain biopsy was culture positive for HSV-2. The patient was placed on intravenous Acyclovir and anticonvulsant therapy. Sequential EEGs showed no cerebral activity, and an MRI taken at 6 weeks demonstrated extensive destruction of the brain parenchyma by cavitary lesions (Fig. 1B). The patient was discharged in a vegetative state requiring a feeding gastrostomy tube and died at age 18 weeks secondary to aspiration.

Neuropathology

Left temporal brain biopsy

This showed shrunken neurons, many of which displayed eosinophilic, "Cowdry type A" intranuclear inclusions (Fig. 2A). Hemorrhage, inflammation and glial reaction were absent. Electron microscopy revealed numerous intranuclear hexahedral virions (Fig. 2C). In situ hybridization [15] using commerical obtained biotinylated DNA probes derived from herpes virus (Enzo Biochemical, New York, N.Y.) showed abundant HSV genome in a large number of cells (Fig. 2B). The corresponding probe for cytomegalovirus (CMV) was negative.

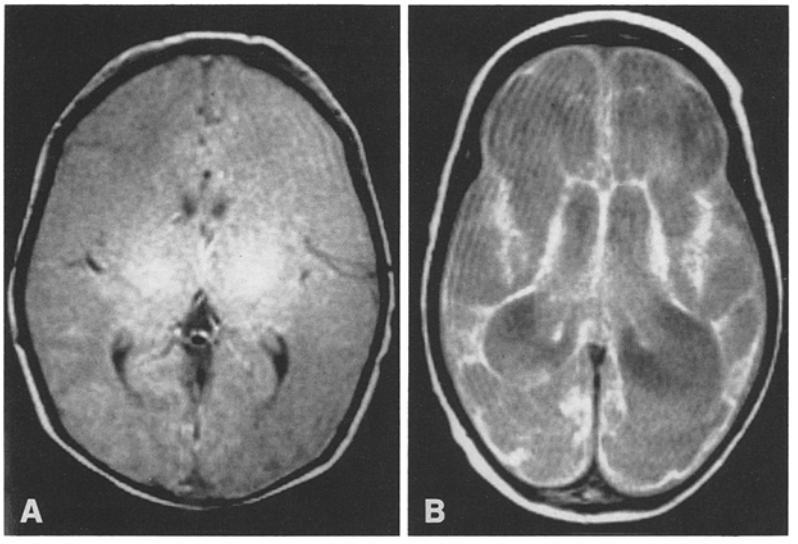

Fig. 1. A Magnetic resonance imaging (MRI) scan performed on day 29 of life shows diffuse loss of gray-white contrast. High-intensity signal limited to basal ganglia and thalami is consistent with the presence of methemoglobin. **B** Follow-up MRI scan at 4 months of age shows multiple cystic cavities of end-stage multicystic encephalopathy

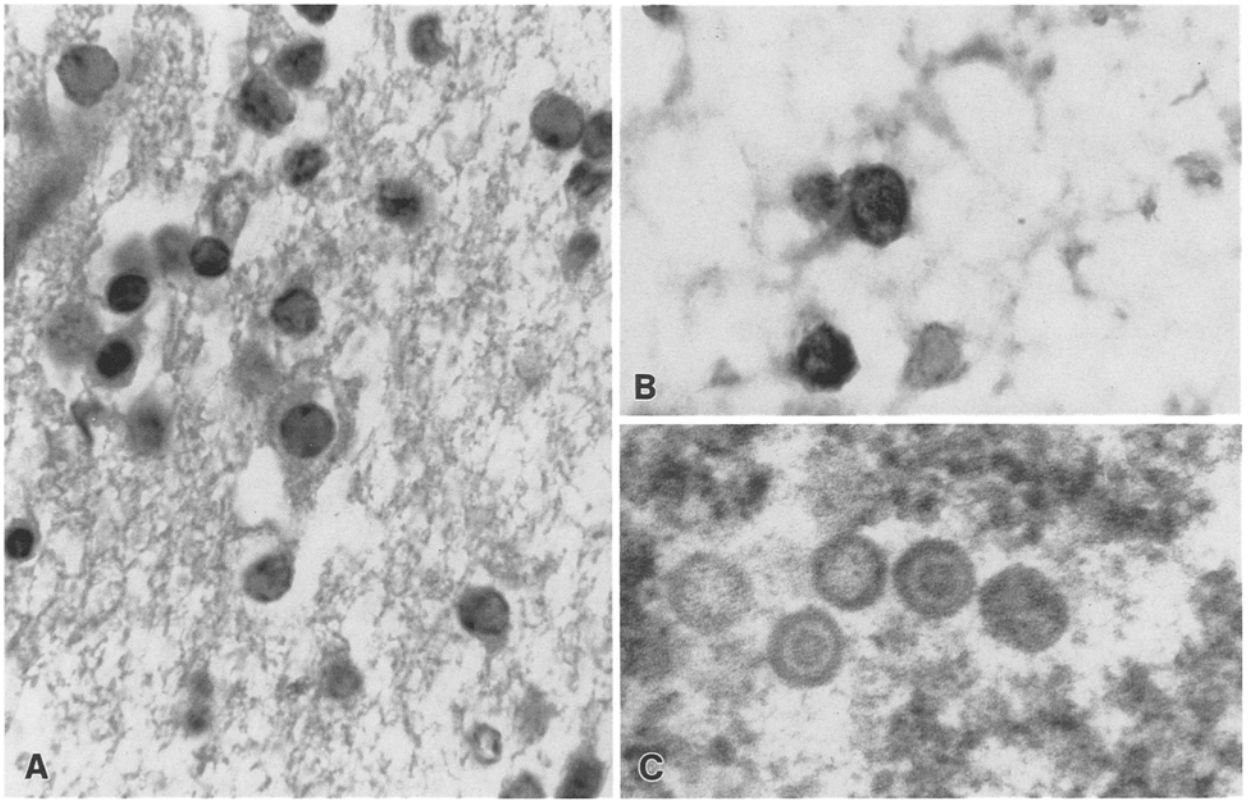

Fig. 2. A Left temporal lobe biopsy demonstrates numerous "Cowdry type A" intranuclear inclusion bodies. H&E, ×400. **B** In situ hybridization probe for Herpes simplex virus (HSV) genome shows abundant granular staining within nuclei. ×1000. **C** Electron microscopy shows viral HSV particles. ×30000

Autopsy findings

Significant pathological findings were limited to the brain which weighed 110 g (normal: 644 g). The leptomeninges were thickened, but blood vessels were unremarkable. The lateral surface of the right temporal lobe was paper thin and smooth; the rest of the cerebral hemispheres showed preservation of the gyral pattern (Fig. 3A). The brain stem was attenuated. Cerebellar hemispheres were moderately atrophic, and the lower part of the vermis was absent, exposing an enlarged fourth ventricle. Cut sections showed marked dilatation of the entire ventricular system. The cerebral parenchyma was largely replaced by multiloculated cystic cavities measuring up to 2.5 cm in diameter (Fig. 3B). The basal ganglia and thalami were atrophic. Rare cystic cavities were present in the midbrain tegmentum. No cystic change was noted in the cerebellum. Microscopic examination revealed dense, gliotic tis-

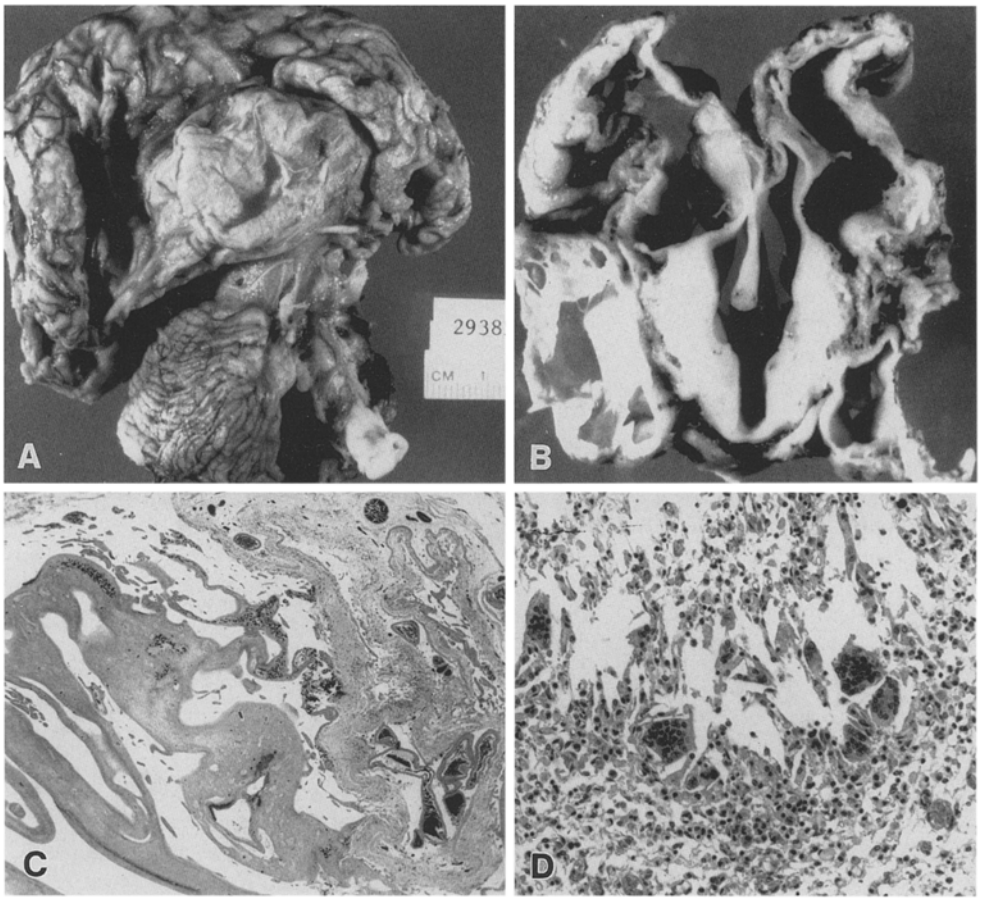

Fig. 3. A Post-fixation brain shows shrunken hemispheres and loss of normal gyral pattern in right temporal lobe. **B** Coronal section of brain showing replacement of normal parenchyma by multiple cystic cavities. **C** Microscopic examination of residual tissue showing dense gliosis and focal calcification. H&E ×10. **D** Focal areas containing macrophages and cholesterol clefts associated with multinucleated giant cells. H&E ×100

sue lining the cavities filled with lipid-laden macrophages and focal dystrophic calcification (Fig. 3C). Hemosiderophages, lymphocytic aggregates and cholesterol clefts with associated multinucleated foreign body giant cells (Fig. 3D) were also identified. The atrophic thalami, basal ganglia and brain stem displayed diffuse gliosis, focal calcification and aggregates of lipid-laden macrophages. The cerebellar cortex was atrophic due to severe neuronal loss in all layers. None of the sections had evidence of active viral infection by light, ultrastructural or in situ examination.

Discussion

This patient developed typical MCE several weeks after an episode of virologically and pathologically proven HSV-2 encephalitis. Neuroimaging studies initially showed a normal brain which progressively evolved into MCE. Although a significant hypoxic episode at some time in the course of the illness may have produced the MCE, there was no documentation that such an event had occurred. Therefore, HSV-2 infection was the most likely cause of this patient's MCE. The association of MCE with HSV, has been inferred by several authors (Table 1). In only one case was HSV isolated from the CSF and brain biopsy. All affected infants were well at birth and thriving until the onset of symptoms which occurred between 12 to 25 days, suggesting that infection occurred during passage through a HSV-infected birth canal. As in many previous reports [11], the mother in this present case did not exhibit clinical evidence of herpes infection. Clinical manifestations of neonatal HSV infections are variable and isolated CNS infection is uncommon. In one series only 5 of 148 cases [10] and in another only 1 of 14 cases [11] of neonatal HSV infection had isolated CNS involvement. The rarity of HSV encephalitis associated with MCE may be due to early regional containment of viral infection by the host immune system or early death from disseminated infection before cystic lesions develop. It is noteworthy that inflammatory or glial responses were absent in the brain biopsy despite abundant intranuclear inclusions. Price et al. [12] reported a patient with Hodgkin's disease who developed widespread HSV-1 encephalitis showing Cowdry type A inclusions and extensive neuronal destruction, but no inflammation. The widespread pathology was attributed to the patient's anergic state. The reasons for the lack of

Table 1. Clinical and pathological findings in reported cases of multicystic encephalopathy

Reference	Age at onset (days)	Sex	Presenting symptoms	Clinical signs and symptoms	Association with HSV
Young et al. [16]	25	F	Focal convulsions	Quadriparesis, blindness, deafness, aspiration	Serology
Haynes et al. [7]	14	M	Convulsions, lethargy	Hypotonia, coma, cardiorespiratory arrest	HSV isolated from skin
Mirra [9]	13	M	Convulsions, lethargy	Quadriparesis	HSV isolated from CSF and brain bx
Farris and Blaw [5]	Not provided	Not provided	Focal convulsions	Progressive obtundation	Serology
Smith et al. [14]	14	F	Focal convulsions	Right hemiplegia, chorio-retinitis, homonymous hemianopia	HSV isolated from skin
Chutorian et al. [1]	12	M	Convulsions, decreased appetite	Quadriparesis	HSV isolated from skin
Present case	14	M	Convulsions, decreased appetite, listlessness	Quadriparesis, blindness, deafness, acute aspiration	HSV isolated from brain bx, electron microscopy, in situ hybridization

Reference	Gross pathology	Microscopy
Young et al. [16]	Cystic cavities involving entire cerebrum; sparing of cerebellum and brain stem; hydrocephalus	Destruction of all cortical neurons, most of the neurons of the thalamus and basal ganglia; astrocytes, macrophages and rare multinucleated giant cells
Haynes et al. [7]	Extremely small brain (125 g); cavities involving entire cerebrum; sparing of cerebellum and brain stem	Advanced cortical necrosis with liquefaction and gliosis
Mirra [9]	Extremely small brain (145 g); cavities involving entire cerebrum; sparing of cerebellum and lower brain stem	Necrotizing "granulomatous" inflammation with macrophages, reactive astrocytes and giant cells; massive calcium deposition; malakoplakia
Farris and Blaw [5]	Not provided	Not provided
Smith et al. [14]	Not autopsied	Not autopsied
Chutorian et al. [1]	Cavities involving entire cerebrum	Not provided
Present case	Extremely small brain (110 g); cavities involving entire cerebrum hydrocephalus	Fibrous bands composed of reactive astrocytes, varying stages of organization with macrophages, giant cells, calcification and cholesterol clefts; focal atrophy of cerebellum

cellular response are not clear in this infant who had no clinical or autopsy evidence of immune deficiency.

In the present case, we were able to document the evolution of MCE from a virologically and pathologically proven HSV-2 encephalitis. At autopsy, 15 weeks after the initial presentation, the virus could not be isolated from the brain, and in situ hybridization studies failed to demonstrate viral genome. These findings are in agreement with studies showing that virus is rarely detected in the brain of patients with HSV encephalitis who died 3 weeks or longer after the onset of the disease [4]. Thus, failure to retrieve virus in MCE does not exclude an infectious etiology in certain cases.

Acknowledgements. We would like to thank John Lee for his technical assistance, Phil Verzola for photography and Barbara Rockafellow for her secretarial assistance.

References

1. Chutorian AM, Miechener RC, Defendini R, Hilal SK, Gamboa ET (1979) Neonatal polycystic encephalomalacia: four new cases and review of the literature. J Neurol Neurosurg Psychiatry 42:154–160
2. Crome L (1958) Multilocular cystic encephalopathy of infants. J Neurol Neurosurg Psychiatry 21:146–152
3. Esiri MM (1982) Viruses and Alzheimer's disease. J Neurol Neurosurg Psychiatry 45: 759–760
4. Esiri MM, Reading MC, Squier MV, Hughes JT (1989) Immunocytochemical characteristics of macrophage and lymphocyte infiltrate in the brain in six cases of human encephalitis of varied etiology. Neuropathol Appl Neurobiol 15:289–305
5. Farris, WA, Blaw ME (1973) Multicystic encephalomalacia in an infant due to herpesvirus hominis type II. Neurology 23:415 (abstr)
6. Friede RL (1988) Development neuropathology, 2nd edn. Springer-Verlag, New York, pp 115–118
7. Haynes RE, Azimi PH, Cramblett HG (1968) Fatal herpesvirus hominis (Herpes simplex virus) infections in children. JAMA 206:312–319
8. Johnson RT (1982) Viral infections of the nervous system, 2nd edn. Raven Press, New York
9. Mirra JM (1971) Aortitis and malacoplakia-like lesions of the brain in association with neonatal Herpes simplex. Am J Clin Pathol 56:104–110
10. Nahmias AJ, Alford CA, Korones SB (1970) Infection of the newborn with Herpesvirus hominis. Adv Pediatr 17:185–226

11. Pettay O, Leinikki P, Donner M, Lapinleimu K (1972) Herpes simplex virus infection in the newborn. Arch Dis Child 47:97–103
12. Price R, Chernik N, Horta-Barbosa L, Posner JB (1973) Herpes encephalitis in an anergic patient. Am J Med 54:222–228
13. Schmitt HP (1989) Multicystic encephalopathy – A polyetiologic condition in early infancy: morphologic, pathogenic and clinical aspects. Brain Dev 6:1–9
14. Smith JB, Groover RV, Klass DW, Houser OW (1977) Multicystic cerebral degeneration in neonatal Herpes simplex virus encephalitis. Am J Dis Child 131:568–572
15. Unger ER, Budgeon LR, Myerson D, Brigati DJ (1986) Viral diagnosis by in situ hybridization. Am J Surg Pathol 10:1–8
16. Young GF, Know DL, Dodge PR (1965) Necrotizing encephalitis and chorioretinitis in a young infant. Arch Neurol 13:15–24